

## CASE REPORT

# Surgical Correction of an Inverse Astigmatic Keratotomy following Penetrating Keratoplasty in a Patient with Keratoconus

<sup>1</sup>Marco Abbondanza, <sup>2</sup>Gabriele Abbondanza

## ABSTRACT

Astigmatic keratotomy (AK) is a common and safe procedure to correct post-penetrating keratoplasty (PKP) astigmatism in patients affected by keratoconus (KC). We report the case of a post-PKP AK that was performed inversely by mistake in a private practice. A new AK was performed by our practice in order to correct the remarkably high astigmatism (19 D) that was created with the previous inverse procedure. Fourteen months later, astigmatism had decreased by 12.9 D and central corneal thickness had increased by 35  $\mu\text{m}$ .

**Keywords:** Astigmatic keratotomy, Cornea, Keratoconus, Keratotomy, Lri, Surgical error.

**How to cite this article:** Abbondanza M, Abbondanza G. Surgical Correction of an Inverse Astigmatic Keratotomy following Penetrating Keratoplasty in a Patient with Keratoconus. *Int J Kerat Ect Cor Dis* 2015;4(3):107-109.

**Source of support:** Nil

**Conflict of interest:** None

## INTRODUCTION

Keratoconus (KC) is a bilateral noninflammatory corneal ectasia, which usually occurs at a young age, often in the second decade of life. This corneal dystrophy results in distorted and decreased vision,<sup>1</sup> although a number of conservative procedures is available.<sup>2</sup> These include corneal collagen cross-linking (CXL),<sup>3</sup> mini asymmetric radial keratotomy (MARK),<sup>4</sup> asymmetric radial keratotomy (ARK),<sup>5</sup> circular keratotomy (CK)<sup>6</sup> and intrastromal corneal ring segments (ICRS).<sup>7</sup>

In 20 to 25% of cases, however, corneal transplantation may be required. In such cases, astigmatic keratotomy (AK), also known as arcuate keratotomy, is a common and safe procedure to correct postoperative astigmatism. The first reference to AK surgery was made in 1885 by

Norwegian ophthalmologist Schiøtz,<sup>8</sup> while Italian surgeon Lucciola of Terrin was the first to adopt non-perforating corneal incisions to correct astigmatism.<sup>9</sup>

We report the correction of a 19 D astigmatism, due to a previous surgical mistake made by a private practice, resulted in an inverse AK, which was performed in an attempt to correct the original post-penetrating keratoplasty (PKP) astigmatism in a patient with bilateral KC.

## CASE REPORT

In September 2013, a 70-year-old man presented with a bilateral KC diagnosed in 1976. Ocular history was complex and included PKP in both eyes in 1978, transplant rejection and, subsequently, new PKP in both eyes in 2000. In 2011, the patient underwent femtosecond laser-assisted AK in the right eye in order to correct postoperative astigmatism in a private practice. Due to a surgical mistake in the operating theater, however, the incisions were not placed on the axis of the steeper meridian, resulting in an inverse procedure and in an opposite effect to that originally planned.

The patient came to our practice with the hope of improving his complex condition. He underwent a thorough clinical examination, which included measurement of uncorrected visual acuity (UCVA) and best corrected visual acuity (BCVA), computerized corneal topography, axial biometry, pachymetry, endothelial cell count, keratometry, Scheimpflug camera corneal analysis and slit-lamp examination. During our examination, central keratometry (K) values in the right eye were  $32 \times 51$  D,  $K_{\text{max}}$  was 70.1 D, central pachymetry (Pentacam—Oculus Optikgerate GmbH, Wetzlar) was 506  $\mu\text{m}$  and thinnest pachymetry was 481  $\mu\text{m}$ . Uncorrected visual acuity was 4/200 and, due to extreme corneal irregularity, the patient was not able to apply contact lenses on his right eye anymore (Fig. 1).

We decided to perform a new AK in order to partially address the previous surgical mistake, we were asked to correct. Factors that were carefully considered included the designation of the corneal clear zone, along with

<sup>1</sup>Head Surgeon, <sup>2</sup>Researcher

<sup>1,2</sup>Department of Surgery, Abbondanza Eye Center, Rome Milan, Italy

**Corresponding Author:** Marco Abbondanza, Head Surgeon Department of Surgery, Abbondanza Eye Center, Rome, Milan Italy, e-mail: info@abbondanza.org

the determination of the position, length and depth of the microincisions, performed with a diamond knife. We opted for a manual AK in order to better place the incisions both in length and position, given that the femtosecond laser cannot perform fully customized incisions based on the tomography. Incisions designed during the surgical plan were marked on a copy of the corneal topography print and were used as a surgical reference during the procedure. The target refractive result was determined at the end of this preoperative decision process. After application of topical anesthesia (benoxinate chloride 0.4%), AK incisions were performed

at 80 to 90% of corneal thickness, with particular attention to corneal irregularity, especially along the steepest axis of astigmatism.

Fourteen months after the intervention, central keratometry (K) values in the right eye were 35.9 × 42 D, K<sub>max</sub> was 56.7 D, central pachymetry was 541 μm and thinnest pachymetry was 519 μm. Uncorrect visual acuity was 3/10 and the patient was able to apply contact lenses on his right eye once again (Fig. 2).

**DISCUSSION**

Today, AK is considered to be a safe procedure for the correction of post-PKP astigmatism<sup>10</sup> and was deemed equally safe and effective both 20<sup>11</sup> and 30 years ago.<sup>12</sup> In terms of difference between femtosecond laser-assisted AK and manual (diamond knife) AK, a comprehensive study shows that no statistically significant variations were detected, highlighting that the only difference between the two techniques was represented by potential microperforations and off-center incisions with manual AK.<sup>13</sup>

In our case, AK, performed with a diamond knife, was successful in strongly improving the patient’s astigmatism, UCVA and in giving him the possibility to use contact lenses on his right eye once again, thus countering the markedly negative effects of the surgical mistake we were asked to address (Table 1). Along with a careful patient selection, factors that are crucial to a positive outcome are quality of the diamond blade and experience of the surgeon with incisional refractive surgery.

At present, nevertheless, it’s worth reminding that corneal collagen CXL is widely considered to be the golden standard technique in the treatment of KC. In one study, we showed that along with the halting of the progression of the disease, CXL with epithelium removal results in an average reduction of corneal curvature of 1.2 D,<sup>14</sup> something that might prevent the need for further surgery in keratoconic eyes, including corneal transplantation and subsequent refractive surgery. These trends let us hope, in the near future, for continuous improvements and less invasive surgery in the treatment of KC.

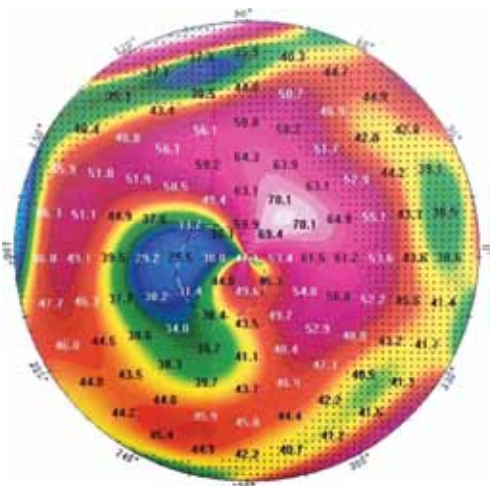


Fig. 1: Corneal topography of the right eye before the intervention, K<sub>max</sub> value was 70.1 D

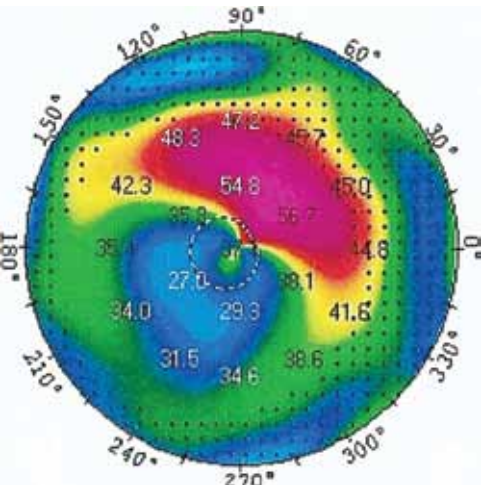


Fig. 2: Corneal topography of the right eye 14 months after the intervention, K<sub>max</sub> and astigmatism strongly improved

Table 1: Pre- and post-AK values, 14 months after the intervention

	<i>K<sub>med</sub></i>	<i>K<sub>max</sub></i>	<i>Central pachymetry</i>	<i>Thinnest pachymetry</i>	<i>Astigmatism</i>	<i>UCVA</i>
Pre-AK	41.5	70.1	506	481	19	4/200
Post-AK	38.95	56.7	541	519	6.1	3/10
Difference	-2.55	-13.4	35	38	-12.9	—



**REFERENCES**

1. Rabinowitz YS. Keratoconus. *Surv Ophthalmol* 1998;42(4): 297-319.
2. Abdelaziz L, Barbara R. History of the development of the treatment of keratoconus. *Int J Keratoconus and Ectatic Corneal Dis* 2013;2(1):31-33.
3. Wollensak G, Spoerl E, Seiler T. Riboflavin/ultraviolet: a induced collagen crosslinking for the treatment of keratoconus. *Am J Ophthalmol* 2003;135(5):620-627.
4. Abbondanza M. Mini cheratotomia radiale asimmetrica (Mini ARK) per la correzione chirurgica del cheratocono in fase iniziale, nell'ipermetropia e nelle miopie lievi. *Esperienze* 1997;12(1):21-24.
5. Abbondanza M. Asymmetric radial keratotomy for the correction of keratoconus. *J Refract Surg* 1997;13(3):302-307.
6. Krumeich JH, Kezirian GH. Circular keratotomy to reduce astigmatism and improve vision in stage I and II keratoconus. *J Refract Surg* 2009;25(4):357-365.
7. Colin J, Cochener B, Savary G, Malet F. Correcting keratoconus with intracorneal rings. *J Cataract & Refract Surg* 2000;26(8):1117-1122.
8. Schiøtz LJ. Hin Fall von hochgradigem Hornhaut-stastigmatismus nach Staarextraction: Bessergung auf operativem Wege. *Arch Augenheilkd* 1885;15:178.
9. Chi YR, Hardten DR, Lindquist TD, Lindstrom RL. Astigmatic Keratotomy. In: Agarwal S, Agarwal A, Buratto L, Apple DJ, Ali JL, editors. *Textbook of Ophthalmology*. New Delhi: Jaypee Brothers Medical Publisher (P) Ltd.; 2002. p. 1152-1166.
10. Nubile M, Carpineto P, Lanzini M, Calienno R, Agnifili L, Ciancaglini M, Mastropasqua L. Femtosecond laser arcuate keratotomy for the correction of high astigmatism after keratoplasty. *Ophthalmol* 2009;116(6):1083-1092.
11. Price FW, Grene RB, Marks RG, Gonzales JS. Astigmatism reduction clinical trial: a multicenter prospective evaluation of the predictability of arcuate keratotomy: evaluation of surgical nomogram predictability. *Arch Ophthalmol* 1995; 113(3):277-282.
12. Sugar J, Kirk AK. Relaxing keratotomy for post-keratoplasty high astigmatism. *Ophthalm Surg* 1983;14(2):156-158.
13. Hoffart L, Proust H, Matonti F, Conrath J, Ridings B. Correction of postkeratoplasty astigmatism by femtosecond laser compared with mechanized astigmatic keratotomy. *Am J Ophthalmol* 2009;147(5):779-787.
14. Abbondanza M, Abdolrahimzadeh B, Zuppardo M. Refractive Changes Following CXL. *Cataract and Refract Surg Today Europe* 2009;4(7):33-38.