

Asymmetric Radial Keratotomy for the Correction of Keratoconus

Author: Marco Abbondanza

Journal of Refractive Surgery, vol. 13, no. 3, pp. 302-307
1997

We have had 10 years of successful experience with asymmetric radial keratotomy in keratoconus, designed to flatten the steeper central and paracentral areas of the cornea. We think the procedure is the treatment of choice for types I, II, and selected cases of type III keratoconus. The procedure does not adversely affect the results of subsequent surgery such as aphakic epikeratoplasty, corneal transplantation, cataract extraction with implantation of an intraocular lens, or glaucoma or retinal and vitreous procedures.

SURGICAL PROCEDURE

Before surgery, pachymetry, keratometry, cycloplegic refraction, and endothelial specular microscopy, including endothelial cell count and study of the cellular morphology, were performed, and intraocular pressure and corneal diameters were measured. In addition, shape section analysis, evaluation of central corneal clarity, and videokeratography with profile comparison using the Topographic Modeling System (Computed Anatomy Inc., New York, NY) and the Keratron (Optikon 2000, Rome, Italy) were performed.

The procedure is contraindicated in patients with less than 300 μm of corneal thickness on the apex of the cornea, in those with a keratometry reading of more than 60.00 diopters (D), and in those with central thick corneal leucomas as determined by

slitlamp microscopy. Clinical contraindications include recurring corneal or mycotic infections, severe dry eye syndrome, and psychological instability.

Preparation for asymmetric radial keratotomy consists of designating the clear zone, delimiting the extent of treatment (30° to 270°) in accordance with the videokeratography, and calculating the number and depth of incisions based on pachymetry.

The procedure itself consists of placing three to twelve centripetal radial incisions in the inferior cornea (keeping them shallow enough to reduce the risk of perforating the apex of the cornea), with as large a central clear zone as possible (from 4.0 to 5.5 mm), always keeping within the ectatic area.

RESULTS

Results in 63 eyes after at least 60 months followup showed that the procedure stopped keratoconus progression and successfully corrected spherical and cylindrical ametropia (Tables 1-3, Figs 1-2). Nine eyes (12%) had a spectacle-corrected visual acuity of 20/20, and more than 25% approximately 20/25. After 6 months, keratometry and pachymetry readings were stable, except in three eyes with type III keratoconus that subsequently underwent corneal transplantation. These three were among the first in whom we performed the procedure, before we clearly understood its limitations. The subsequent penetrating keratoplasty was not adversely affected by this previous surgery.

Immediately after surgery, some patients experienced photophobia and fluctuation of visual acuity, but these problems resolved after 10 to 60 days.

Unwanted microperforations were rare, seldom required treatment (one eye required suturing with a 10/0 nylon), and had no significant effect on the final result. They tended to occur in eyes in which the corneal thickness was substantially irregular, especially in those with type III keratoconus. To help prevent such microperforations, incisions should be no more than 80% of corneal thickness.

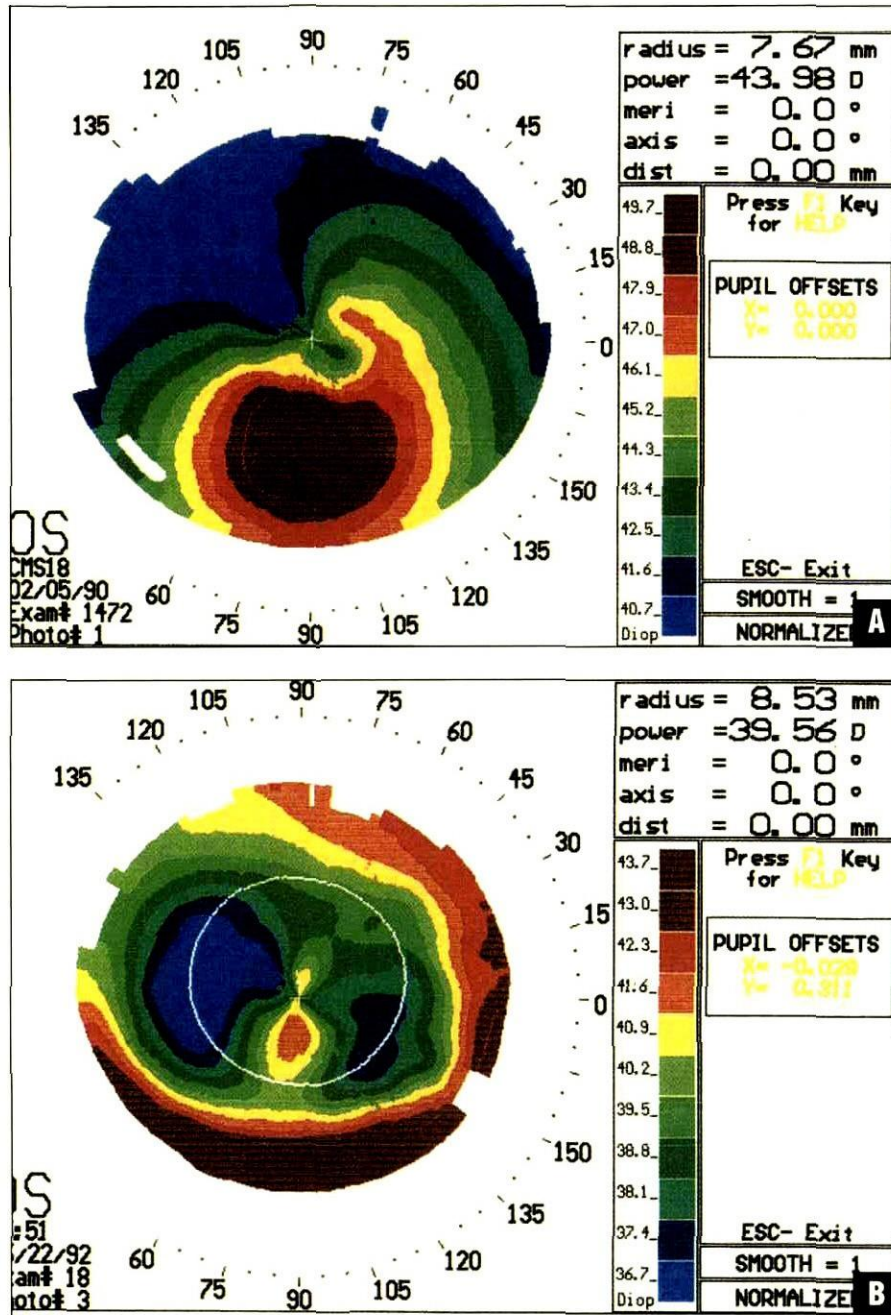


Figure 1: Asymmetric radial keratotomy for keratoconus. A) Videokeratograph shows type I keratoconus with inferior steepening. B) Postoperative videokeratograph shows resolution of the inferior steepening, with a central steep zone surrounded by a bowtie pattern of flattening.

The final results depended on diameter of the clear zone, number of incisions, depth of incisions, deepening of incisions, size of the treated asymmetric corneal area (from 30° to 180° to 270°), quality of the diamond knife blade, the surgeon's ability to perform a regular and constant 80% incision depth, and the surgeon's incisional surgery experience.

All patients with bilateral keratoconus chose to have the procedure performed on their second eye.

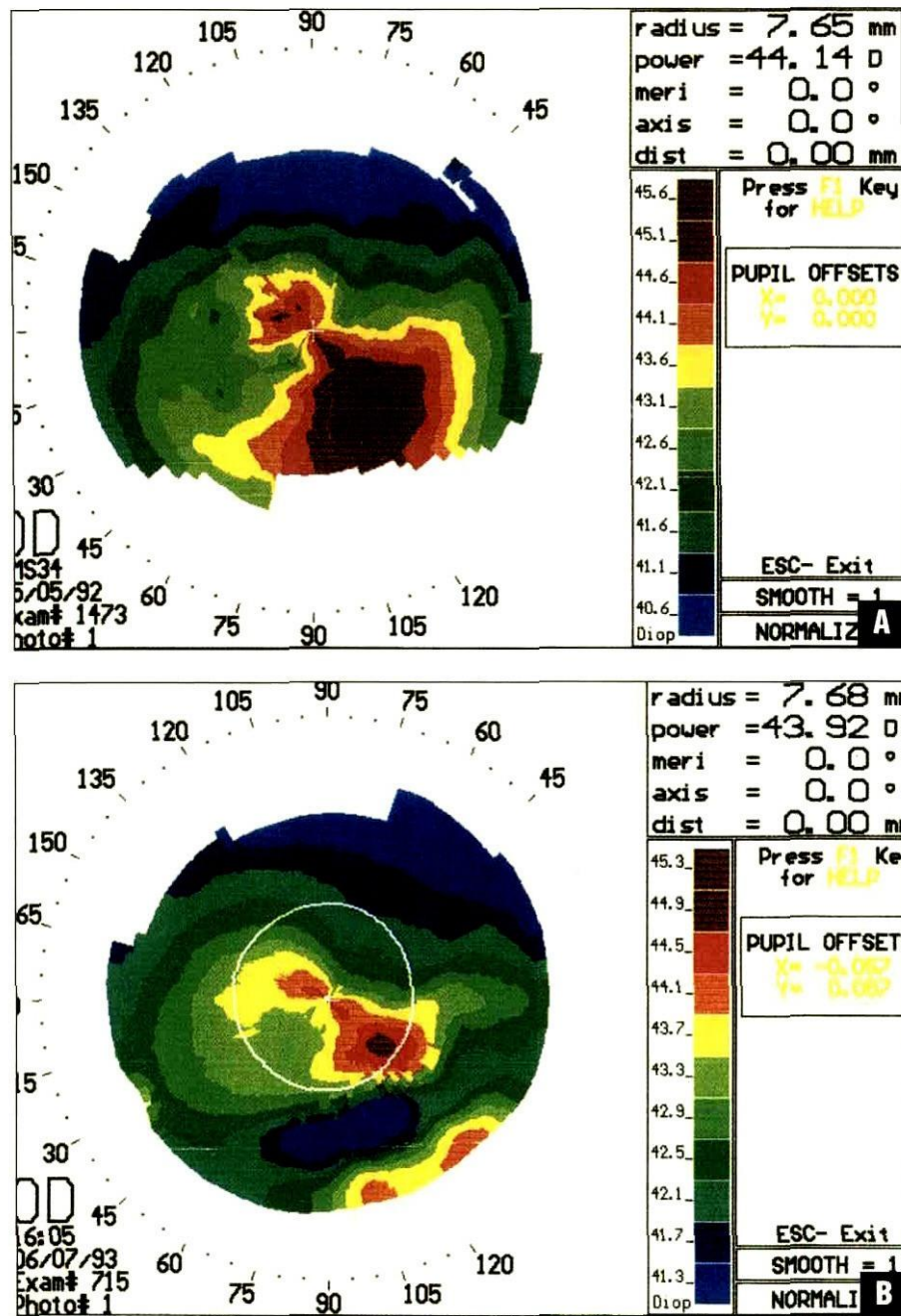


Figure 2: Asymmetric radial keratotomy for keratoconus. A) Videokeratograph shows keratoconus in the right eye with inferonasal steepening. B) After surgery, a large area of steepening is replaced by a focal area of flattening, with a residual central steep zone.

Table 1 Asymmetric Radial Keratotomy in 22 Eyes with Type I Keratoconus				
Patient Initials, Eye	Before Surgery		After Surgery	
	Keratometric Values (D)	Visual Acuity	Keratometric Values (D)	Visual Acuity
BF, right	45.00	20/28	39.50 to 41.76	20/28
IU, right	44.00 to 49.00	20/66	38.50 to 41.50	20/33
PA, left	40.50 to 44.00	20/26	37.00 to 40.00	20/20
BS, right	44.00 to 47.50	20/21	41.50 to 42.50	20/21
CD, left	41.50 to 45.50	20/20	39.00 to 43.50	20/20
IG, right	45.00 to 48.50	20/40	42.50 to 44.50	20/30
IG, left	44.00 to 45.00	20/25	43.00	20/20
BZ, right	42.50 to 44.50	20/20	42.00	20/20
BZ, left	45.50 to 49.00	20/40	39.50 to 40.50	20/28
DA, right	44.50 to 48.50	20/125	33.00 to 39.00	20/100
DA, left	45.00 to 48.50	20/80	34.00 to 40.00	20/33
FA, right	43.00 to 47.00	20/100	39.00 to 40.00	20/28
VG, right	42.50 to 45.00	20/25	36.00 to 38.00	20/20
VG, left	44.00 to 47.50	20/28	36.50 to 39.50	20/20
CD, right	43.50 to 44.50	20/66	43.00 to 44.00	20/50
FA, right	41.50 to 43.50	20/25	40.00 to 43.00	20/28
FA, left	42.00 to 44.00	20/28	35.00 to 40.00	20/25
SS, right	45.00 to 47.00	20/25	43.00	20/20
FA, left	43.00 to 45.50	20/33	38.50 to 39.00	20/33
GS, left	41.50 to 44.50	20/20	40.50 to 44.00	20/20
GA, right	43.50 to 44.00	20/21	41.00 to 42.00	20/20
GA, left	43.00 to 44.00	20/25	41.00 to 42.50	20/25
Average	43.43 to 46.06	20/30	39.47 to 41.76	20/25
Average astigmatism (D)	2.63		2.29	
Average percent improvement				20 (1 Snellen line)
Sector amplitude 45°	42.59 to 44.40		39.40 to 41.40	
1 to 3 incisions				
(average for 11 eyes)				
Average astigmatism (D)	1.81		2.00	
Average visual acuity (% improvement)		20/26		20/24 (8)
Sector amplitude 90°	44.25 to 47.58		39.54 to 42.08	
3 to 5 incisions				
(average for 11 eyes)				
Average astigmatism (D)	3.33		2.54	
Average visual acuity (% improvement)		20/35		20/26 (34)

Table 1: Asymmetric Radial Keratotomy in 22 Eyes with Type I Keratoconus

Table 2
Asymmetric Radial Keratotomy in 25 Eyes with Type II Keratoconus

Patient Initials, Eye	Before Surgery		After Surgery	
	Keratometric Values (D)	Visual Acuity	Keratometric Values (D)	Visual Acuity
IU, left	45.00 to 52.00	20/80	43.00 to 44.50	20/28
PA, right	45.00 to 51.00	20/66	38.00 to 43.50	20/28
GM, left	47.00 to 49.00	20/66	44.00 to 47.50	20/33
BS, left	48.50 to 51.50	20/57	44.00 to 47.00	20/25
CA, right	51.00 to 52.00	20/36	45.00 to 46.00	20/30
CA, left	51.00 to 54.00	20/57	46.00 to 50.00	20/36
LG, right	49.50 to 54.00	20/36	44.00 to 45.50	20/33
SF, right	52.00 to 55.00	20/44	44.00 to 46.00	20/25
NB, right	51.50 to 53.00	20/100	40.50 to 42.50	20/40
NB, left	47.00 to 49.00	20/50	40.50 to 43.00	20/33
MS, right	47.00 to 49.00	20/66	44.00 to 46.50	20/44
CD, right	47.00 to 54.00	20/80	43.50 to 49.50	20/40
PG, left	47.50 to 51.50	20/33	41.00 to 43.00	20/25
SM, left	49.00 to 51.00	20/100	38.00 to 43.00	20/28
LF, right	46.00 to 49.50	20/26	41.00	20/24
LF, left	51.50 to 55.50	20/44	40.50 to 42.50	20/30
CD, left	45.00 to 53.00	20/100	44.00 to 46.00	20/66
SS, left	46.50 to 49.50	20/100	40.00 to 44.00	20/33
ML, right	49.50 to 54.50	20/100	40.50 to 44.00	20/33
ML, left	46.50 to 50.00	20/57	41.50 to 46.00	20/30
MA, right	45.50 to 48.00	20/33	45.00 to 48.00	20/28
CS, right	49.00 to 52.50	20/66	44.00 to 48.50	20/57
CS, left	51.00 to 55.00	20/130	45.50 to 49.50	20/80
GG, right	45.00 to 54.00	20/66	42.00 to 46.50	20/44
GG, left	44.00 to 50.00	20/100	40.50 to 43.50	20/44
Average	47.91 to 52.08	20/60	42.45 to 45.37	20/32
Average astigmatism (D)	4.17		2.92	
Average improvement (%)				81 (3 Snellen lines)
Sector amplitude 135° 5 to 7 incisions (average for 16 eyes)	46.36 to 50.93		41.66 to 44.96	
Average astigmatism (D)	4.57		3.30	
Average visual acuity (% improvement)		20/60		20/32 (85)
Sector amplitude 180° 7 to 9 incisions (average for 9 eyes)	50.66 to 54.00		43.33 to 46.05	
Average astigmatism (D)	3.34		2.72	
Average visual acuity (% improvement)		20/57		20/36 (55)

Table 2: Asymmetric Radial Keratotomy in 25 Eyes with Type II Keratoconus

Table 3 Asymmetric Radial Keratotomy in 16 Eyes with Type III Keratoconus				
Patient Initials, Eye	Before Surgery		After Surgery	
	Keratometric Values (D)	Visual Acuity	Keratometric Values (D)	Visual Acuity
BF, left*	45.00 to 62.00	20/400	44.00 to 53.00	20/100
GM, right	54.00 to 58.00	20/130	50.00 to 54.00	20/66
GM, right	51.00 to 56.00	20/100	45.00 to 47.00	20/33
DP, right	57.00 to 62.00	20/200	43.50 to 48.50	20/80
DP, left	54.00 to 62.00	20/200	44.50 to 50.50	20/80
SF, left	54.50 to 57.00	20/57	43.00 to 45.00	20/25
CE, left	50.00 to 56.00	20/57	38.50	20/50
MS, left	52.00 to 54.00	20/200	50.00 to 53.00	20/50
BM, right	51.00 to 63.00	20/80	42.50 to 46.50	20/40
BM, left*	48.00 to 60.00	20/130	58.00 to 60.00	20/100
SM, right	54.00 to 59.00	20/125	39.00 to 44.00	20/33
SC, right	55.00 to 60.00	20/200	46.50 to 48.00	20/28
SC, left	59.00 to 60.00	20/200	51.00 to 52.00	20/33
FM, right	49.00 to 59.00	20/100	40.00 to 46.00	20/36
MA, left*	56.00 to 59.00	20/100	58.00 to 61.00	20/100
GS, right	54.00 to 59.00	20/200	42.00 to 49.50	20/57
Average	52.72 to 59.10	20/125	46.00 to 49.78	20/50
Average astigmatism (D)	6.38		3.78	
Average improvement (%)				170 (4 Snellen lines)
Sector amplitude 180° to 225° 9 to 11 incisions (average for 6 eyes)	52.10 to 57.50		43.00 to 46.65	
Average astigmatism (D)	5.41		2.65	
Average visual acuity (% improvement)		20/85		20/36 (134)
Sector amplitude 225° to 270° 11 to 16 incisions (average for 10 eyes)	53.10 to 60.10		47.70 to 52.20	
Average astigmatism (D)	7.00		4.50	
Average visual acuity (% improvement)		20/180		20/55 (215)
* Keratoconus worsened, transplantation, no subsequent problems				

Table 3: Asymmetric Radial Keratotomy in 16 Eyes with Type III Keratoconus

DISCUSSION

In radial keratotomy, symmetric and radial corneal incisions flatten the central part of the cornea, with the effect increasing as the incisions become longer and deeper. With asymmetric radial keratotomy in keratoconus, the steeper central and paracentral cornea are flattened. The mechanism by which the procedure benefits patients with keratoconus is that the flattened corneal profile eliminates corneal ectasia, allowing a more even distribution of pressure in the anterior chamber. Also, the gradual healing

of the incisions in tissues rich with fibrin creates a strong support for corneal stroma, which, before the procedure was tectonically relatively thin and weak. Thus, the original defect is unlikely to recur. Professor Fyodorov has demonstrated these effects in radial keratotomy, and they have been supported by a wealth of cytological and histological data, and by histopathology. The healing of incisions in patients with keratoconus requires more time.